



UNIVERSIDAD NACIONAL AUTÓNOMA DE MÉXICO

Facultad de Medicina

División de Estudios de Posgrado

Hospital General “Dr. Manuel Gea González”

División de Cirugía Plástica Estética y Reconstructiva

TÍTULO:

**CORRELACIÓN CLÍNICA – TOMOGRÁFICA DE LA DEFORMIDAD TORÁCICA
CLÍNICA EN LOS PACIENTES CON MICROTIA UNILATERAL
POSTOPERADOS DE RECONSTRUCCIÓN AURICULAR CON CARTÍLAGO
COSTAL**

TESIS QUE PARA OBTENER EL GRADO DE SUB-ESPECIALISTA EN:

CIRUGÍA PLÁSTICA ESTÉTICA Y RECONSTRUCTIVA

PRESENTA: DR. JOHNATAN FIGUEROA PADILLA

ASESOR DE TESIS: DRA CLAUDIA GUTIÉRREZ GÓMEZ

México DF. a 24 de Julio de 2014



Universidad Nacional
Autónoma de México

Dirección General de Bibliotecas de la UNAM

Biblioteca Central



UNAM – Dirección General de Bibliotecas
Tesis Digitales
Restricciones de uso

DERECHOS RESERVADOS ©
PROHIBIDA SU REPRODUCCIÓN TOTAL O PARCIAL

Todo el material contenido en esta tesis esta protegido por la Ley Federal del Derecho de Autor (LFDA) de los Estados Unidos Mexicanos (México).

El uso de imágenes, fragmentos de videos, y demás material que sea objeto de protección de los derechos de autor, será exclusivamente para fines educativos e informativos y deberá citar la fuente donde la obtuvo mencionando el autor o autores. Cualquier uso distinto como el lucro, reproducción, edición o modificación, será perseguido y sancionado por el respectivo titular de los Derechos de Autor.

Este trabajo de tesis con **No. 05-30-2011** presentado por el Dr. Johnatan Figueroa Padilla, se presenta en forma con visto bueno por el tutor principal de la tesis: Dra. Claudia Gutiérrez Gómez adscrita al servicio de Cirugía Plástica Estética y Reconstructiva en este hospital con fecha del 24 de Julio del 2014 para su impresión final.


DRA. CLAUDIA GUTIÉRREZ GÓMEZ

ASESORA DE TESIS E INVESTIGADORA RESPONSABLE

AUTORIZACIONES

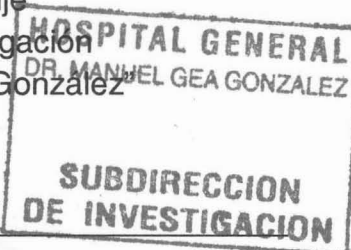
CORRELACION CLÍNICA - TOUSOPÁRICA DE LA DEFORMIDAD TORÁCICA
CLÍNICA EN LOS PACIENTES CON BRONQUITIA UNILATERAL
POSTOPERADOS DE RECONSTRUCCIÓN ARTICULAR

Dr. Octavio Sierra Martínez
Director de Enseñanza e Investigación
Hospital General "Dr. Manuel Gea González"



COLABORADORES:

Dra. María Elisa Vega Memije
Presidente del Comité de Investigación
Hospital General "Dr. Manuel Gea González"



Dr. Antonio Fuente Del Campo
Jefe de la División de Cirugía Plástica Estética y Reconstructiva
Hospital General "Dr. Manuel Gea González"

Dra. Claudia Gutiérrez Gómez
Médico Adscrito al servicio de Cirugía Plástica Estética y Reconstructiva
"Hospital General "Dr. Manuel Gea González"

**CORRELACIÓN CLÍNICA – TOMOGRÁFICA DE LA DEFORMIDAD TORÁCICA
CLÍNICA EN LOS PACIENTES CON MICROTIA UNILATERAL
POSTOPERADOS DE RECONSTRUCCIÓN AURICULAR CON CARTÍLAGO
COSTAL**

COLABORADORES:

DRA. CLAUDIA GUTIÉRREZ GÓMEZ

DRA. MARCIA PÉREZ DOSAL

DR. OMAR JAIMES RAMÍREZ

Agradecimientos

A mis profesores Fernando Ortiz-Monasterio QEPD, Fernando Molina Montalva, Claudia Gutiérrez Gómez, Eric Santamaría Linares, Carlos Gargollo Orvañanos, Sergio Lozano Téllez, Jacobo Felemovicius Hermangus, Alexander Cárdenas Mejía, Salvador Medina Sánchez, Javier López Mendoza, Héctor Cantú Martínez y Marcia Pérez Dosal, por ser ejemplos a seguir, por su enseñanza, guía y apoyo brindados durante mi estancia en la residencia de cirugía plástica y por su puesto a mi jefe de servicio Dr. Antonio Fuente del Campo por su tutoría.

A la doctora Claudia Gutiérrez Gómez por su motivación, asesoría y consejos brindados. Por su disposición y prontas acciones para la realización de este proyecto y por formar un gran universo de pacientes a su cargo.

Al Dr. Omar Jaimes Ramírez y al resto del equipo de Radiología e imagen por su disposición, enseñanza en su materia y por facilitar la realización de los estudios y mediciones correspondientes.

A mis compañeros y amigos residentes por su continuo apoyo para cumplir con las arduas tareas propias de la residencia médica.

A mis grandes amigos Alexandro Aguilera Salgado, Andrés Bello Margalef, José de Jesús Cortés Arreguín, Cuauhtémoc Lorenzana Sandoval y Armando Valdés Rodríguez por impulsarme y hacerme sentir afortunado de vivir hombro a hombro con ellos una etapa inolvidable de mi entrenamiento.

Clinical and Tomographic Evaluation of Thoracic Deformities in Unilateral Auricular Reconstruction with Autologous Costal Cartilage: A Useful Tool for Proper Monitoring

Johnatan Figueroa¹, Claudia Gutierrez¹, Omar Jaimes¹, Wendy Hinojosa¹, Daniela Tellez¹, and Fernando Molina¹

Abstract

Background: Thoracic deformity after costal cartilage harvesting is a poorly reported complication in current literature. Several authors reconstruct an ear using 3 or 4 costal cartilages. This method produces various chest wall deformities. There is no description of an analysis of thoracic deformity as a sequel in patients who underwent autologous auricular reconstruction based on a clinical and tomographic evaluation.

Methods: We performed a prospective analysis of 40 patients who underwent auricular reconstruction after harvesting rib cartilage of a single hemithorax, with one year follow up. All patients underwent clinical analysis and measurements of each hemithorax using computed tomography (CT) scan one year after removing rib cartilage.

Results: The tomographic analysis diagnosed 70% of thoracic deformity, but only 30% of those deformities were clinically evident in this series.

Conclusion: Removing three or more costal cartilages causes clinically evident thoracic deformity in 30% of the patients, while up to 70% of the defects can be detected by CT scan, because a mild deformity is not noticeable clinically. This analysis indicates that there is an underestimation of thoracic deformities after reconstruction with autologous cartilage. We suggest that CT scan and its multiple modalities are essential for comprehensive evaluation of these patients.

Keywords: Auricular reconstruction; thoracic deformity; rib cartilage

¹M.D., Hospital "Dr. Manuel Gea González", Mexico City.

1 Introduction

Deformity of the rib cage after harvesting costal cartilage for auricular reconstruction is a complication that occurs in young patients who undergo this procedure for microtia. This deformity becomes more apparent as the child grows, which is of great importance because it alters the patient's body image. A clinical and tomographic evaluation of these patients will determine the deformity associated with costal cartilage harvesting and its true frequency. Thus, we can analyze our results to make a correlation between the thoracic deformity evaluated clinically and the thoracic deformity evaluated by CT.

CT scan also allows us to define grades of deformity, which represents a guideline not reported yet in the literature for thoracic morphology assessment, even through three-dimensional reconstruction. It will also be useful in making a future correlation with possible alterations in ventilatory mechanics.

In current literature there are no reports of tomographic evaluation for thoracic deformities in these particular patients, although it is known that it represents a potential complication despite the refinements in surgical techniques.

The aim of this study was to evaluate the correlation between a thoracic deformity diagnosed clinically and a deformity diagnosed by tomography. This way we demonstrate the practical utility of this resource to obtain valuable data in the evaluation of patients after auricular reconstruction with costal cartilage, but mainly we show its usefulness in the diagnosis of patients who escape the surgeon's appreciation.

2 Materials and Methods

We performed a prospective analysis of 40 patients who underwent auricular reconstruction using costal cartilage of one hemithorax, with at least one year follow up in the period from January 2006 to January 2011. All patients underwent clinical evaluation by the plastic surgery team in charge. This assessment included a description of alterations in the surface and contour of the chest wall, asymmetries in the position of the nipple areola complex (NAC), differences in muscle morphology at the sternocostal junction, differences in height between pectoral muscles on each side of the chest and the presence of thoracic scoliosis, defined as a difference in height among costal arches.

All patients were evaluated with a chest computed tomography using a Siemens Scanner Somatom Sensation 64-slice and images were visualized using a syngo fastView 2.0 software. The reports were made by a single radiologist who ignored the clinical test results. The same radiologist made the measurements using as reference a coronal cut at T7 vertebral body level, then a transverse line passing through the center of the costal cartilage donor zone, and at this level an axial cut was made to measure the anteroposterior diameter of both hemithoraces at their central portion, from the posterior chest wall to the point of greatest projection on the anterior chest wall. The same was done for the transverse diameter of both hemithoraces in their most lateral points. We also observed the bony and cartilaginous structures of the rib cage in the three-dimensional reconstruction with special attention to the spatial configuration of the sternum, cephalic, caudal and lateral ribs to the donor site, comparing them with the healthy contralateral side. Results were documented.

For the statistical validation we used the chi-square as a nonparametric test to prove the statistical significance in the difference between proportions among clinical and

tomographic diagnosis; we also used kappa index to test the concordance between CT scan and clinical evaluation.

3 Results

3.1 Clinical Assessment

We analyzed the clinical and radiological reports of 40 patients who underwent auricular reconstruction with costal cartilages harvested from one hemithorax at least a year from the first surgical event. There were 26 men and 14 women aged between 11 and 37 years old (mean 17).

Alterations on the surface and contour of the chest wall were found in 12 patients. The deformities were more noticeable in the male group, consisting of a collapse at the level of the scar that extended from the sternum to the lateral portion of the donor site (Figure 1).

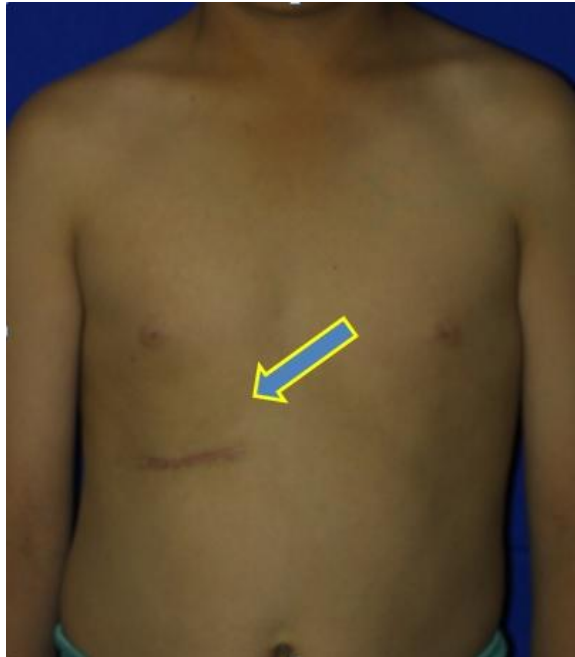

Figure 1: Collapse at the level of the scar from the sternum to the lateral portion of the donor site.

In severe cases the collapse was associated with a compensatory bulge in the most lateral and cephalic portion of the cartilage donor site (Figure 2).

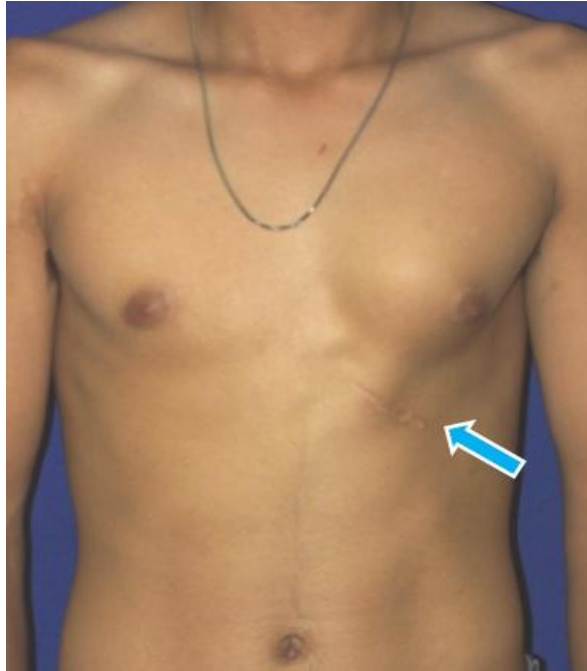

Figure 2: Compensatory bulge in the donor site.

Thirteen patients had NAC asymmetries. The most noticeable issue was found on the intervened side, where the NAC was in a more cephalic and lateral position than the NAC on the healthy hemithorax. This difference in height ranged from 2 to 20 millimeters (Figure 3). We observed differences in the pectoralis major muscle insertions between both hemithoraces.

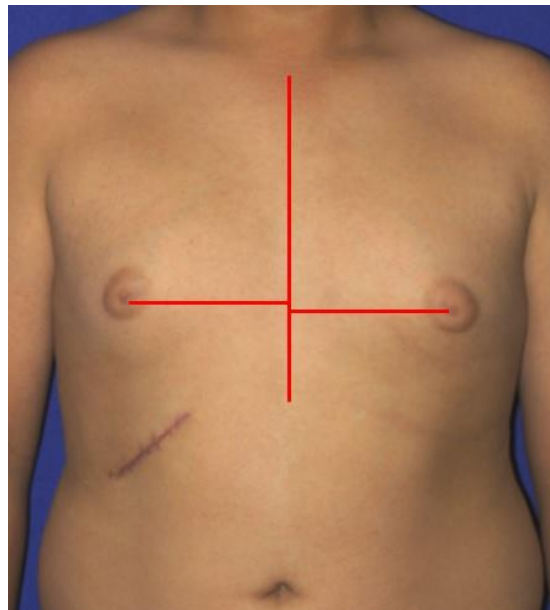

Figure 3: NAC asymmetries. NAC is more cephalic and lateral on the donor side than in the healthy hemithorax.

On the intervened side, the mid sternal and the muscular bundles insertions within the rib cage were substantially modified to a more cephalic position. This produces a muscular bulge that clinically resembles gynecomastia, which in this case series was observed in 3 men (Figure 4 and 5).

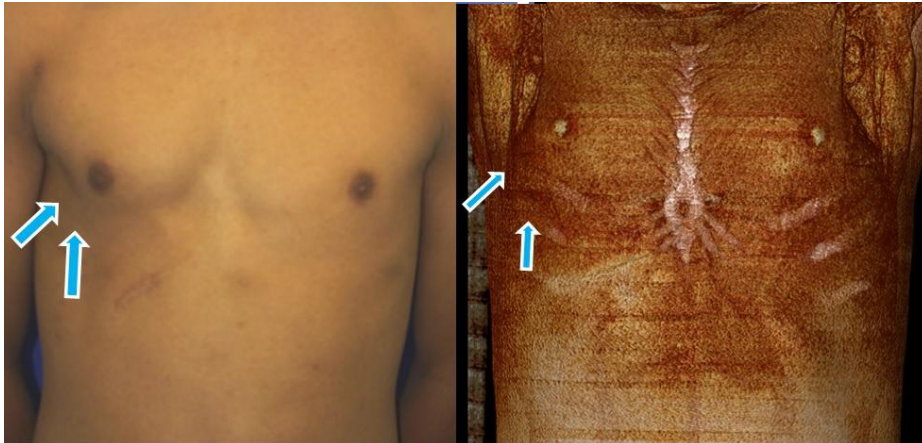


Figure 4: Muscular insertions within the rib cage modified to a more cephalic position.

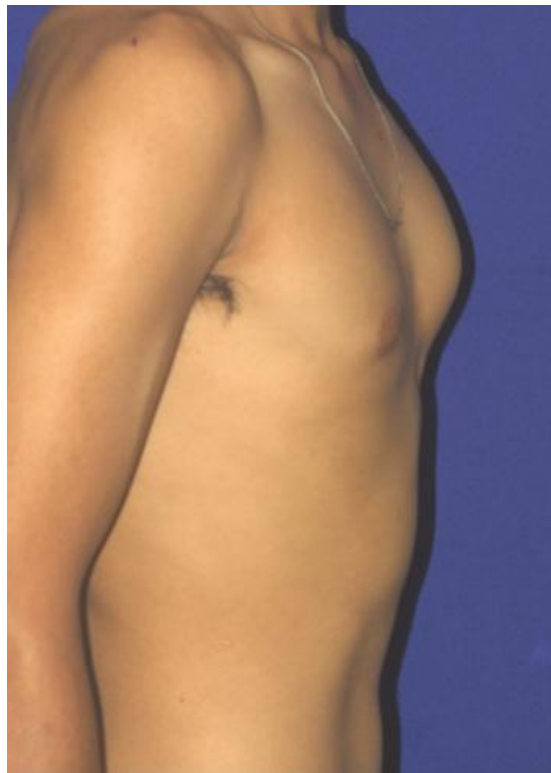

Figure 5: Muscular bulge resembling gynecomastia.

Finally, we documented one case of thoracic scoliosis. This finding was characterized by a marked deviation of the sternum and an uneven bone-cartilage complex on the side where the cartilage was removed (Figure 6).

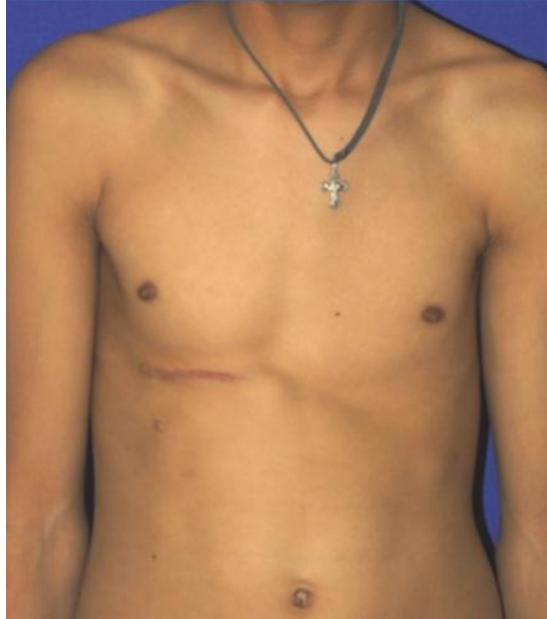

Figure 6: Marked deviations of the sternum and uneven bone-cartilage complex on the donor side.

3.2 Tomographic Assessment

For this assessment we used the healthy hemithorax as a parameter. The difference in the anteroposterior diameter between both hemithoraces was measured and for classification purposes we suggest that when there is a difference between 1 to 4mm the deformity is mild, from 5 to 9 mm the deformity is moderate and when it is greater than 10 the deformity is severe. (Figure 7).

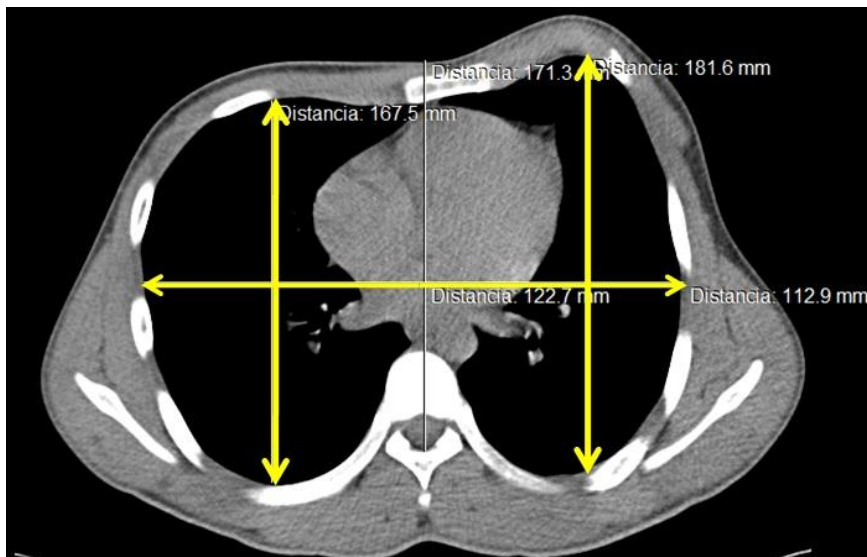


Figure 7: Tomographic assessment to classify the degree of the deformity. Measurement of the anteroposterior diameter of both hemithoraces.

In our study group, 28 patients with a deformity on CT scanning were identified. Among this group, 57% (n=16) belonged to the group of a mild deformity. It is noteworthy that this group was not diagnosed with a thoracic deformity by means of clinical assessment. In other words, just 12 of the 28 patients diagnosed by CT scan were identified to have a deformity in the clinical evaluation. This difference of proportion was statistically significant ($p = 0.01$) (Figure 8).

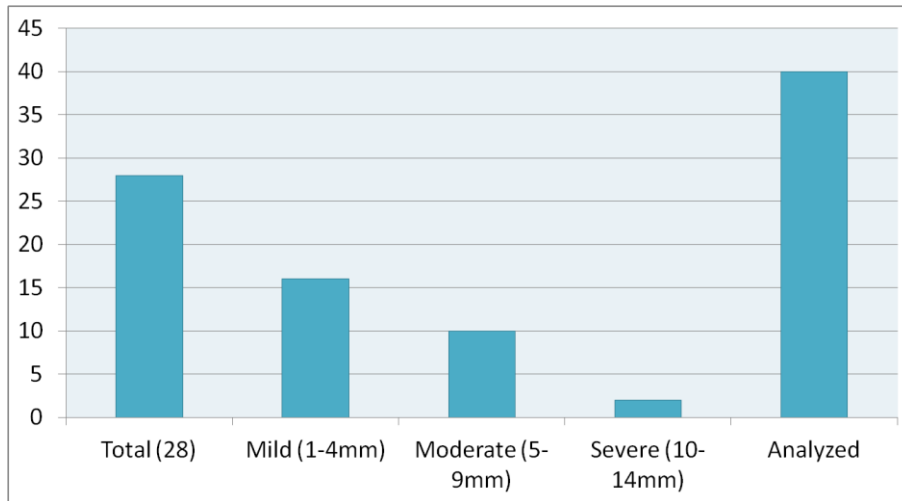


Figure 8: CT scan assessment of deformity.

Twenty males (76.9%) had thoracic deformity on CT scan and only ten had clinical manifestations. In females the deformity by CT was identified in eight cases and only two of them had clinical manifestations. The difference in sex ratios resulted not statistically significant ($p = 0.173$). A Kappa index of 0.310 means a low level of concordance between clinical and CT assessment.

4 Discussion

Thoracic deformity is a potential complication of costal cartilage harvesting and most existing reports are short-term follow-ups [1,2]. It is well known that CT is an effective tool for the screening of various bony and soft tissue structures all over the body; however, it is poorly used for the evaluation and management of patients who underwent an elective reconstructive procedure.

There are previous studies that describe the age of the patient as a determining factor in the decision of performing the first procedure of cartilage harvesting. Netscher reports that the main costal growth occurs in the first 4 years of life and a second peak occurs between 12 and 18 years old [3]. Later, Ohara identified a mechanical factor where the donor costal arches deepen as an effect of muscular forces. This is an undeniable fact in our study, where we found that the change in height in the insertion of the pectoralis major muscle produces obvious bulging similar to those reported by this author [4]. Tanzer reported deformities in up to 50% of the patients; but in his series of 44 patients he evaluated the results of 3 different techniques of cartilage harvesting. In our study, we evaluated the results employing the same technique using the seventh to ninth costal

cartilages with perichondrial sparing. However, costal cartilage harvesting was not performed by the same surgeon due to the residency program at our institution [5].

Thomson took cartilage in patients between 2 and 3 years of age and found deformities in 33% of the cases and only in 8% when taken between 6 and 12 years of age. He also described various deformities by clinical analysis [6]. Our CT scan analysis reported deformities in 70% (n=28) of the cases; 22% (n=9) occurred in the group under 10 years old and 48% (n=19) in the group over 10 years old. Nevertheless, the deformity was clinically evident in only 30% of the patients in this series, and the most affected group was the group under 10 years of age, where the most severe cases were found. Brent reported 600 cases, reporting the level of satisfaction of patients taking into account the thoracic contour and scar, but no thoracic deformity was reported in a long-term follow-up. Nagata reported 270 cases in which he returned remaining cartilage to the perichondrium in the donor area, thus finding no thoracic deformity during his follow-up. No author employs a clinical correlation with CT scanning [7,8].

For all of the above, we implemented an improvement to the clinical analysis and we suggest an objective method for the evaluation of thoracic deformities in order to obtain reproducible descriptions and define study groups that will help identify potential problems in long-term follow-up.

5 Conclusion

Taking three or more costal cartilages causes deformity clinically evident in 30% of the cases, while this study detected deformities in 70% of the cases by CT scan. A mild deformity is not clinically obvious and the anteroposterior chest diameter is the most affected in these cases. Changes in muscular insertions observed in severe cases cause a deformity that resembles gynecomastia. We also noticed that the younger the patient at the first procedure the greater the thoracic deformity; plus the deformity is more evident in men. The collapse and deviation from central thoracic structures is oriented towards the donor site. Given the results, we propose CT scanning as an essential tool for a comprehensive evaluation of these patients, since mild deformities are frequently clinically overlooked.

References

- [1] S.W.Laurie, L.B. Kaban, J.B. Mulliken, J.E. Murray, Donor-site morbidity after harvesting iliac bone, *Plast Reconstr Surg*, 73(6), (1984), 933-938.
- [2] C.A. Skouteris, G.C. Sotereanos, Donor site morbidity following harvesting of autogenous rib grafts, *J Oral Maxillofac Surg*, 47(8), (1989), 808-812.
- [3] D.T. Netscher, R. Peterson, Normal and abnormal development of the extremities and trunk, *Clin Plast Surg* 17(1), (1990),13-21.
- [4] K. Ohara, K. Nakamura, E. Ohta, Chest wall deformities and thoracic scoliosis after costal cartilage graft harvesting, *Plast Reconstr Surg*, 99(4), (1997),1030-1036.
- [5] R.C. Tanzer, Microtia—a long-term follow-up of 44 reconstructed auricles, *Plast Reconstr Surg*,61(2), (1978), 161-166.

- [6] H.G.Thomson, T.Y. Kim, S.H. Ein, Residual problems in chest donor sites after microtia reconstruction: a long-term study, *Plast Reconstr Surg*, 95(6), (1995), 961-968.
- [7] B. Brent, Auricular repair with autogenous rib cartilage grafts: two decades of experience with 600 cases, *Plast Reconstr Surg*, 90(3),(1992), 375-376.
- [8] Y. Kawanabe, S. Nagata, A new method of costal cartilage harvest for total auricular reconstruction: part I. Avoidance and prevention of intraoperative and postoperative complications and problems, *Plast Reconstr Surg*, 117(6), (2006), 2011-2018.