

**A New Autosomal Recessive Syndrome Consisting of
Posterior Microphthalmos, Retinitis Pigmentosa,
Foveoschisis, and Optic Disc Drusen is Caused by a *MFRP*
Gene Mutation**

**Raul Ayala-Ramirez,¹ Federico Graue-Wiechers,¹ Violeta Robredo,¹ Monica
Amato-Almanza,³ Iliana Horta-Diez,⁴ Juan Carlos Zenteno.^{2,3}**

Departments of ¹Retina, ²Genetics and ³Research Unit, Institute of Ophthalmology
“Conde de Valenciana”, Mexico City, Mexico.

⁴Department of Neuro-ophthalmology, National Institute of Neurology and
Neurosurgery “Manuel Velasco Suarez”, Mexico City, Mexico.

Correspondence to: Juan Carlos Zenteno, MD, PhD. Unidad de Investigación, Instituto
de Oftalmología “Conde de Valenciana”, Chimalpopoca 14, Col. Obrera, Mexico City,
06800, Mexico. Telephone: (5255) 55 88 46 00 ext 3212. E-mail:
jczenteno@salud.gob.mx



Universidad Nacional
Autónoma de México



UNAM – Dirección General de Bibliotecas
Tesis Digitales
Restricciones de uso

DERECHOS RESERVADOS ©
PROHIBIDA SU REPRODUCCIÓN TOTAL O PARCIAL

Todo el material contenido en esta tesis esta protegido por la Ley Federal del Derecho de Autor (LFDA) de los Estados Unidos Mexicanos (México).

El uso de imágenes, fragmentos de videos, y demás material que sea objeto de protección de los derechos de autor, será exclusivamente para fines educativos e informativos y deberá citar la fuente donde la obtuvo mencionando el autor o autores. Cualquier uso distinto como el lucro, reproducción, edición o modificación, será perseguido y sancionado por el respectivo titular de los Derechos de Autor.

Abstract
Introduction
Materials and Methods
Results
Discussion
Acknowledgments
References

ABSTRACT

Purpose: To describe the clinical and genetic characteristics of a new ophthalmic syndrome which consists of posterior microphthalmos, retinitis pigmentosa, foveoschisis, and optic disc drusen that segregates as an autosomal recessive trait in a family with four affected siblings. The *MFRP* (Membrane-type Frizzled-Related Protein) and *CHX10* (CEH10 Homeodomain-Containing homolog) genes, previously implicated in autosomal recessive forms of nanophthalmos/microphthalmos, were analyzed as candidate genes for this novel disease.

Methods: Complete ophthalmologic examinations were performed in four affected siblings and their parents. Ophthalmologic manifestations, fundus photographs, ultrasonographic (US) assessment, electroretinography (ERG), fluorescein retinal angiography (FA), Goldmann kinetic perimetry (GKP), and optical coherence tomography (OCT), as well as mutational status of *MFRP* and *CHX10* genes in genomic DNA.

Results: In all affected siblings, ophthalmologic examination demonstrated normal horizontal corneal diameters and high hyperopia; funduscopy, ERG and FA evidenced a progressive retinal dystrophy compatible with retinitis pigmentosa; A- and B-mode ultrasonography revealed decreased axial eye length and optic disc drusen; OCT showed localized macular retinoschisis. *MFRP* molecular analysis disclosed a 1 base pair insertion in exon 5 (c.498_499insC) in all affected individuals, a mutation that predicts a truncated protein(P165fsX198). Both parents were heterozygous for the mutation.

Conclusions: A distinct autosomal recessive ophthalmic syndrome characterized by microphthalmos, retinitis pigmentosa, foveoschisis, and optic disc drusen is described. We demonstrated that this clinical association is caused by a mutation in *MFRP*, a gene

previously implicated in isolated nanophthalmos. Our data indicate that defects in *MFRP* could be responsible for syndromic forms of microphthalmos/retinal degeneration and that this gene is necessary for photoreceptor maintenance.

INTRODUCTION

Precise regulation of axial eye growth during embryonic life is essential for development and maintenance of emmetropia [1]. Microphthalmos is a structural malformation in which ocular globes exhibit a total axial length at least 2 standard deviations below age-similar controls [2,3] or, more generally, globes with an anteroposterior diameter of less than 20 mm in adults [4]. The anomaly is classified into simple or pure microphthalmos if no other major eye malformations are present, and in complex microphthalmos when additional ocular defects are identified [4,5]. Clinical and genetic data indicates that microphthalmos and the more severe anophthalmos are different manifestations of a same clinical spectrum of eye malformations. Approximately 80% of subjects with microphthalmos/anophthalmos exhibit accompanying systemic malformations [6] and more than 100 syndromic entities displaying microphthalmos/anophthalmos have been recognized in the literature [4,7].

Posterior microphthalmos is an uncommon subtype of microphthalmos defined by reduced total axial length in the presence of a normally sized cornea. This condition is frequently associated to additional eye findings as high hyperopia and papillomacular retinal folds [3,8-10]. Although most instances are sporadic, some familial cases of posterior microphthalmos have been identified, with autosomal recessive inheritance being the most probable way of transmission [3,8]. Posterior microphthalmos must be distinguished from nanophthalmos, a structural anomaly characterized by the combination of microphthalmos, microcornea, and a tendency toward spontaneous or postsurgical uveal effusions [11,12]. Nanophthalmos is sometimes referred to as “simple microphthalmos” [13,14]. The short distance between the lens and retina in eyes with posterior microphthalmos or nanophthalmos causes extreme hyperopia with refractive defects ranging between +8.00 to +25.00 diopters. Typically, posteriorly

microphthalmic/nanophthalmic eyes have an axial length of 13-18.5 mm and are associated with a shallow anterior chamber, and thickening of both the choroidal vascular bed and sclera [15,16].

The clinical combination of posterior microphthalmos/nanophthalmos and retinitis pigmentosa has been recognized in a number of subjects, leading to the assumption that this would represent a discrete syndromic entity [16-20]. There is some evidence that the association can be transmitted as an autosomal recessive trait [16] although most cases have been sporadic.

Here we present the clinical and genetic data of a family in which a novel phenotypic association of posterior microphthalmos, retinitis pigmentosa, foveoschisis, and optic nerve head drusen, segregates as an autosomal recessive trait in four siblings. We propose that this complex phenotype is a new syndromic entity and demonstrated that the disease is caused by a homozygous mutation in *MFRP*, a gene previously implicated in isolated nanophthalmos [21].

Materials and Methods

Clinical Studies

Ophthalmological examinations included best-corrected visual acuity (BCVA), slit-lamp and dilated fundus examination, applanation tonometry, fundus photography, A-mode and B-mode ultrasound examination, electroretinogram (ERG), fluorescein retinal angiography (FA), Goldmann kinetic perimetry (GKP), and optical coherence tomography (OCT). All affected subjects underwent systemic evaluation by a geneticist.

Molecular Genetic analyses

The proband, her parents, and three affected siblings participated in the study after providing informed consent to a protocol that was approved by the Institutional Review Board. Genomic DNA was obtained in each subject from peripheral blood lymphocytes according to standard methods. The entire coding sequences and exon/intron boundaries of both the *MFRP* (Membrane-type Frizzled-Related Protein, located at 11q23.3, 13 exons) and *CHX10* (CEH10 Homeodomain-Containing homolog, 14q24.3, 5 exons) genes were amplified by PCR using pairs of primers derived from the normal published sequences (Ensembl sequences ENST00000261980 and ENST00000360167, respectively). Primer sequences and annealing temperatures for PCR are available on request. Direct sequencing of PCR amplified products from both genes was performed using the Big Dye Terminator Cycle Sequencing kit (Applied Biosystems, Foster City, CA, USA) adding ~10 ng of template DNA in each reaction. Samples were run in an ABI Prism 310 Genetic Analyzer (Applied Biosystems).

Results

Clinical Findings

The propositus was a 49-year-old woman who presented with progressive impairment of night vision and bilateral progressive decrease in visual acuity, both starting about 25 years ago. Her past medical history was unremarkable. She was born from a consanguineous Mexican marriage (parents were second cousins). Three of her 6 siblings complained of similar symptoms. At her first examination, BCVA was 20/200 with a +17.50 diopters (d) refractive error (RE) in the right eye (OD) and 20/100 with a +16.50 d RE in the left eye (OS). Biomicroscopy revealed horizontal corneal diameters (HCD) of 11.2mm OD and 11.5mm OS, normal pupillary light reaction, shallow anterior chambers, narrow angles, and no corneal or lens opacities in both eyes. Applanation intraocular pressures were 18 millimetres of mercury (mmHg) in the OD and 16mmHg in the OS. Fundus examination revealed optic disc pallor with evident optic disc drusen, minimal vascular attenuation, blunting of the macular reflex, pigmentary changes characterized by pigment clumps and “bone-spicule” pigmentation of the midperipheral and peripheral retina in both eyes (figure 1a,b). Axial lengths measured by ultrasound were 15.74 mm OD and 16.08 mm OS. Diffuse scleral thickening was also observed on ultrasound. Optic discs drusen were confirmed by a B-scan (Figure 2e,f)). The ERG showed an extinguished rod response and barely registrable cone responses, bilaterally. FA demonstrated autofluorescence of the optic disc drusen (figure 2a,b) as well as choroidal transmission hyperfluorescence corresponding to retinal pigment epithelium (RPE) atrophy as well as blockage hypofluorescence localized to areas of pigment clumping and “bone-spicule” pigmentation (figure 2c,d). GKP disclosed an inferior arciform scotoma and a 10° superior nasal field reduction OD and concentric reduction of the visual field that

partially affects the fixation point in the inferior sector with a nasal island of 30° OS. OCT showed diffuse macular thickening (408 μM), outer retinal layers schisis with discrete bridging elements at the fovea, absence of a foveal pit and no evidence of macular cysts (figure 3). Clinical examination failed to demonstrate additional somatic anomalies, mental retardation or hypoacusia.

Three affected siblings (two males aged 45 and 39 years and a female aged 41) were also examined. All of them complained of progressive decrease in visual acuity and nyctalopia of onset in the third decade of life. Ophthalmologic examination in these subjects revealed high hyperopia, normal horizontal corneal diameters, shallow anterior chamber, optic disc drusen, and optic nerve head pallor, pigment clumping and “bone-spicule” pigmentation in both midperiphery and periphery, and minimal vascular attenuation (figures 1c-h). All had a reduced axial eye length, increased scleral thickness, and optic disc drusen, demonstrated by US. ERG evidenced extinguished rod responses with moderate to severe damage in cone responses. GKP disclosed features ranging from a complete visual field to a markedly concentric reduction. OCT analysis revealed foveoschisis and absence of foveal pit (figure 3). None of them exhibited systemic alterations or evidence of mental retardation or hypoacusia. Table 1 summarizes ophthalmologic findings in all affected patients.

Molecular Genetic Findings

Mutation analysis of the *MFRP* gene in the four affected patients showed a novel homozygous one base-pair insertion at position 499 (designated c.498_499insC) in the coding region (exon 5). The mutation leads to a shift of the open reading frame and causes a premature truncation of the protein, 33 codons downstream (P165fsX198) (figure 4, middle panel). The predicted truncated protein lacks almost all functional important parts of MFRP, most likely leading to a complete loss of functional protein.

Both parents were heterozygous for the mutation (figure 4, upper panel). In addition, a T to C change in *MFRP* nucleotide 698 (exon 5) was observed in some subjects. This change does not alter the encoded histidine at residue 180 of the protein (His180His). A previously described inconsequential C to T change in *CHX10* nucleotide 471 (exon 3) predicting a silent Ser157Ser polymorphism was observed in all affected subjects. No deleterious mutations were detected in *CHX10*.

Discussion

The complex ocular phenotype in the family described here is uniformly transmitted as an autosomal recessive trait that includes posterior microphthalmos, retinitis pigmentosa, foveoschisis, and optic nerve head drusen. We propose that this disease is a new ophthalmologic genetic syndrome as, to the best of our knowledge, no similar phenotype has been documented previously.

There are several reports of familial phenotypes exhibiting some features observed in this family. For example, in 1958 Hermann [22] reported a kindred with microphthalmos in 13 members of 4 generations, some of them also having pigmentary retinopathy and glaucoma (MIM #157100); Franceschetti and Gernet [23] described in 1965 a non-consanguineous sibship containing 4 individuals with microphthalmia, normally sized corneas, high-grade hypermetropia, macrophakia, retinal degeneration (fundus flavimaculatus/albipunctatus), and dental anomalies; a probable autosomal recessive pattern of inheritance was postulated for this association (MIM #251700). Mackay et al. (1987) [18] examined a consanguineous family with nanophthalmos, cystoid macular degeneration, nyctalopia, restriction of visual fields, high hyperopia, and diffuse choroidal thickening; with age, angle closure glaucoma and pigmentary maculopathy were evident. Clearly, all these phenotypes are dissimilar from that observed in the family described here due to the constant findings in our patients of foveoschisis and optic disc drusen. Interestingly, the combination of nanophthalmos, retinitis pigmentosa, and optic disc drusen was observed in a 68-year-old man studied by Buys et al. in 1999 [16]. This subject also present high hyperopia, microcorneas, and chronic angle closure glaucoma; to our knowledge, this sporadic case has the closest phenotypic similarity with the subjects in our family; however, in that case the authors considered the possibility of a secondary pseudo-retinitis pigmentosa. Finally, a male

subject with nanophthalmos, closed-angle glaucoma, microcornea and pigmentary retinal dystrophy was described by Ghose et al. 1985 [17]. Normally sized corneas and foveoschisis, invariably present in our cases, were absent in that patient.

Clinical and ERG data in all four affected siblings described here indicates the presence of rod degeneration with residual function of cones. Compared to younger patients, older subjects had evidence of worsened cone function, which indicates the progressive nature of the retinal dystrophy. In all four affected subjects, foveoschisis was demonstrated by OCT. This is an interesting finding which could be related to the posterior microphthalmos. It is well known that papillomacular retinal folds frequently develop in subjects with nanophthalmos/microphthalmos, presumably arising from a disparity in growth between the sclera and retina [24]. However, in our patients there was no clinical, fluorangiographic or OCT evidence of papillomacular retinal folds. Some reports of autosomal recessive isolated foveoschisis have been published [25], but no OCT studies are available in these instances to compare with our patients.

Another constant finding in our patients was drusen of the optic disc evidenced clinically and corroborated by both US and autofluorescence phenomenon. Optic disc drusen are deposits of hyaline calcific material within the head of the optic nerve. They have an estimated incidence of 0.3% in the general population and occur most frequently as a bilateral anomaly which sometimes can be inherited in an autosomal dominant fashion [26]. Optic discs containing drusen are often described as small and crowded, lacking a physiologic cup. This anatomic arrangement could predispose to the formation of optic disc drusen, which are thought to be the result of a disturbance of axoplasmic transport at the lamina cribosa, resulting in the extrusion of mitochondria filled with calcium crystals [27]. Although optic disc drusen is observed in approximately 9% of subjects with retinitis pigmentosa [28], we consider that drusen is

a characteristic finding of this syndrome as all four affected siblings in this family exhibit this anomaly.

We attempted to identify the underlying molecular defect causing the disease in this family using a candidate gene approach. We choose to analyze *MFRP* and *CHX10* genes as homozygous mutations in these loci have recently shown to be responsible for autosomal recessive forms of nanophthalmos/microphthalmos [21,29]. A homozygous one pair base insertion in exon 5 of *MFRP* was identified in all affected subjects; the mutation results in a frame-shift yielding 33 aberrant amino acids after residue 165 and a shortened protein of 198 residues compared to the 579 in wild-type *MFRP*. Both parents were heterozygous for the mutation. The predicted protein lacked the two cubilin-related, the two low-density lipoprotein receptor-related, and the C-terminal CRD (cysteine rich) -Frizzled-related domains.

This is the first demonstration that *MFRP* defects can originate microphthalmos in conjunction with retinal degeneration. Sundin et al. recognized *MFRP* mutations in three non-related nanophthalmic families [21]. Based in the observed phenotypes, the authors proposed that *MFRP* is not critical for retinal function, as patients entirely lacking *MFRP* have good refraction-corrected vision, produce clinically normal electroretinograms, show only modest anomalies in the dark adaptation of photoreceptors and have no RPE pigment clumping suggestive of photoreceptor death. However, our patients presented a severe rod-cone dystrophy with retinal hyperpigmentation and serious ERG disturbances. These data suggest that *MFRP* is needed for photoreceptor maintenance and that some of its mutations can result in retinal degeneration. The reason why some *MFRP* mutations cause isolated nanophthalmos while others can affect additional eye structures (as in our patients) is

not clear. Modifier factors, genetic or environmental, could be responsible for this clinical variability.

It is interesting to note that the recessive mouse retinal degeneration mutation *rd6* (*Mfrp*^{*rd6*}) is a splicing mutation in the orthologous *Mfrp* gene causing small, white retinal spots and progressive photoreceptor degeneration similar to that observed in human flecked retinal diseases [30]. Notably, microphthalmia is not a feature of *Mfrp*^{*rd6*} mice [30,31].

Five independent *MFRP* mutations have been described to date (including the reported here), 3 of them being located in exon 5 of the gene [21]. Although more data are needed, these results suggest that exon 5 is a hotspot for *MFRP* mutations. *MFRP* is predominantly expressed in the retinal pigment epithelium and encodes a membrane protein which has a C-terminal domain related to the Wnt-binding domain of the Frizzled (Fz) family of transmembrane proteins. Frizzled proteins are receptors for the Wnts, a family of cell-cell signaling molecules that mediate cell fate determination during development [32]. In recent years it has become evident the critical role of the Wnt/Fz signaling pathway during retinal development [33] and although no formal evidence exists to date that MFRP binds to Wnt proteins, if this relation is established our results will expand the spectrum of inherited eye diseases caused by mutations in molecules regulating of the WNT/Fz signaling pathway [34].

The panocular phenotype observed in our patients (microphthalmia, retinitis pigmentosa, foveoschisis, and optic disc drusen) suggests that *MFRP* plays a wider role in eye development than previously suspected, functioning not only as a regulator of axial eye length. In summary, we present evidence that a genetic defect in *MFRP* causes a new autosomal recessive syndrome of microphthalmos and retinitis

pigmentosa. *MFRP* mutations could be responsible for other inherited human diseases combining abnormally sized eyes and retinal degeneration.

Acknowledgments

The authors thank Dr. Leticia Perdiz for ultrasound studies and Dr. Carmen Lizana for her helpful comments. Financial support was provided by the “Conde de Valenciana” Foundation.

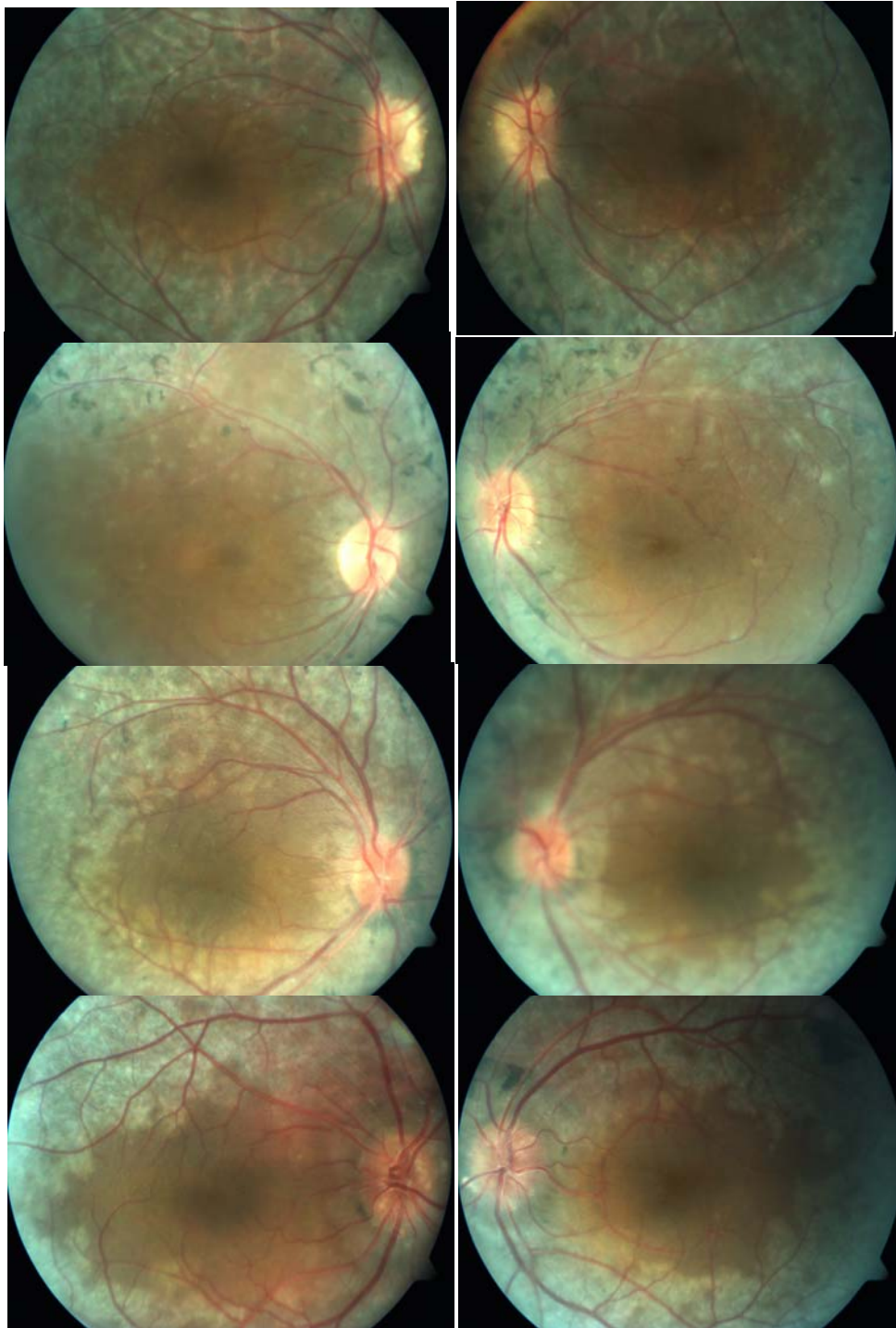


Figure 1.- Fundus photographs of patient #1 (propositus) (a,b) and affected siblings patient #2 (c,d), #3 (e,f), and #4 (g,h). Left column: OD; right column: OS. Optic disc drusen, pigment clumping, bone-spicule pigmentation, blunting of the macular reflex and minimal vascular attenuation are observed.

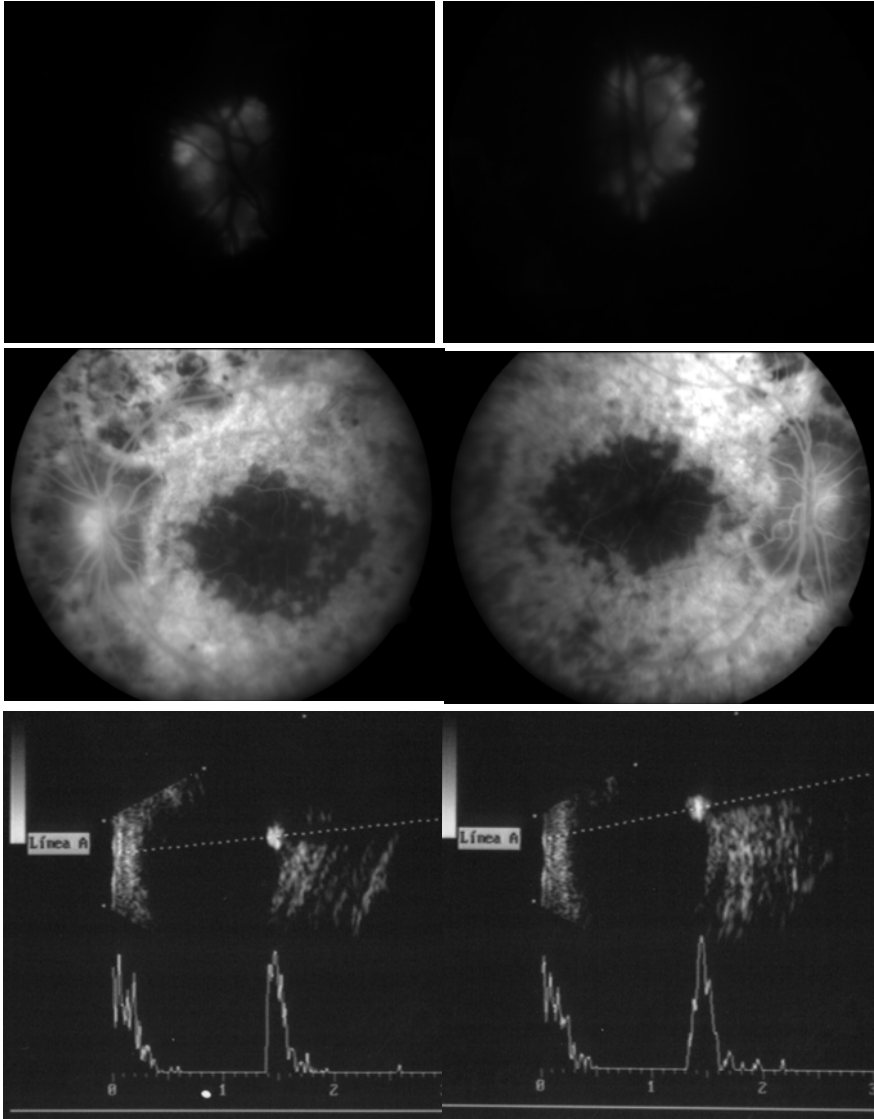


Figure 2.- Fluorescein angiography and ultrasound studies in patient #1. Autofluorescence phenomenon due to optic disc drusen (a,b); fluorescein angiography arteriovenous phase revealed choroidal transmission hyperfluorescence corresponding to retinal pigment epithelium atrophy as well as blockage hypofluorescence localized to areas of pigment clumping (c,d).. B-mode ultrasound showing decreased axial length and optic disc drusen (e,f). Left column: OD; right column: OS.

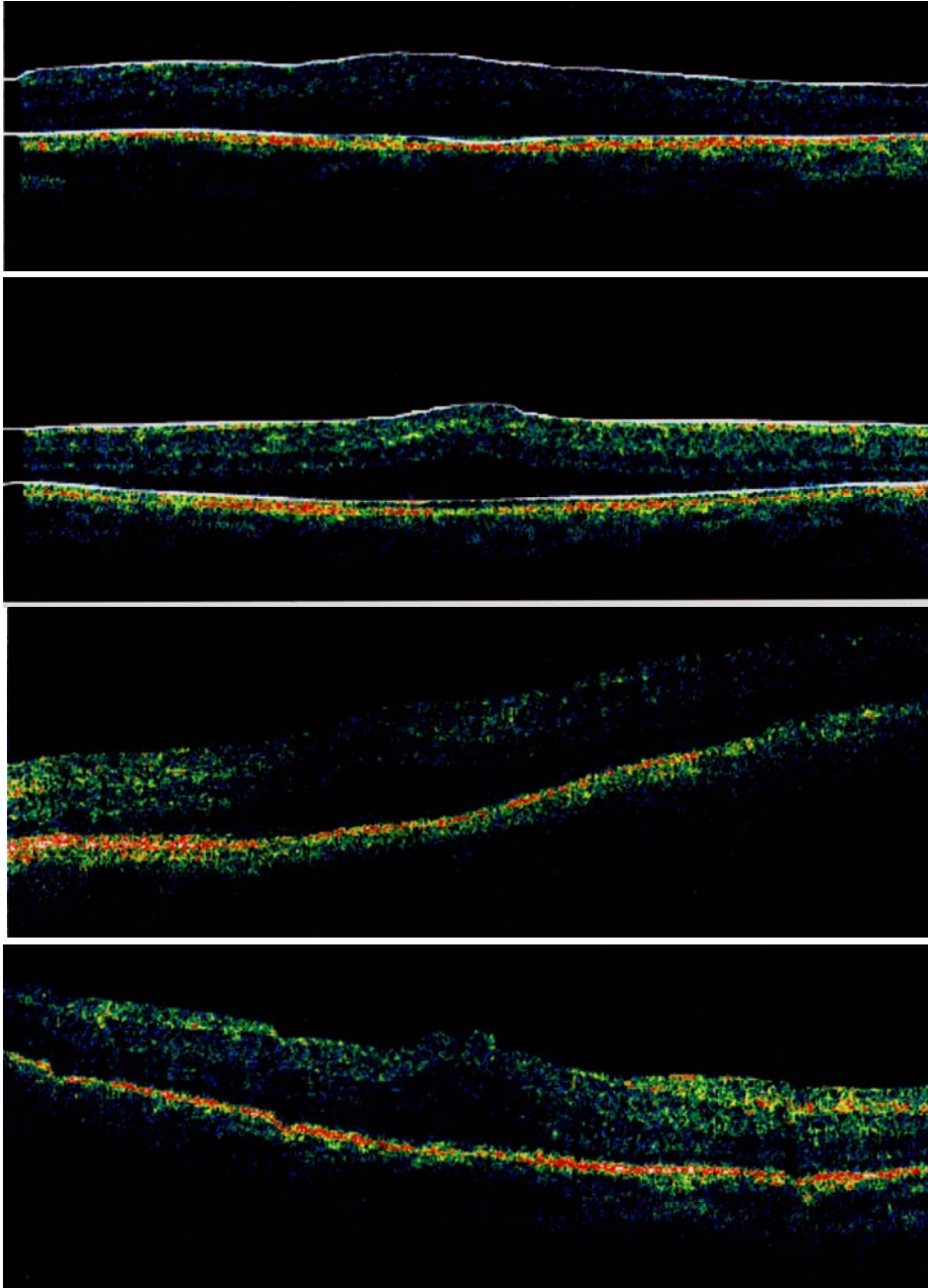


Figure 3.- Optical coherence tomography images in patients #1 (OS), #2 (OS), #3 (OD), and #4 (OD). Diffuse macular thickening, outer retinal layer schisis with discrete bridging elements (foveoschisis) were evident in all affected subjects.

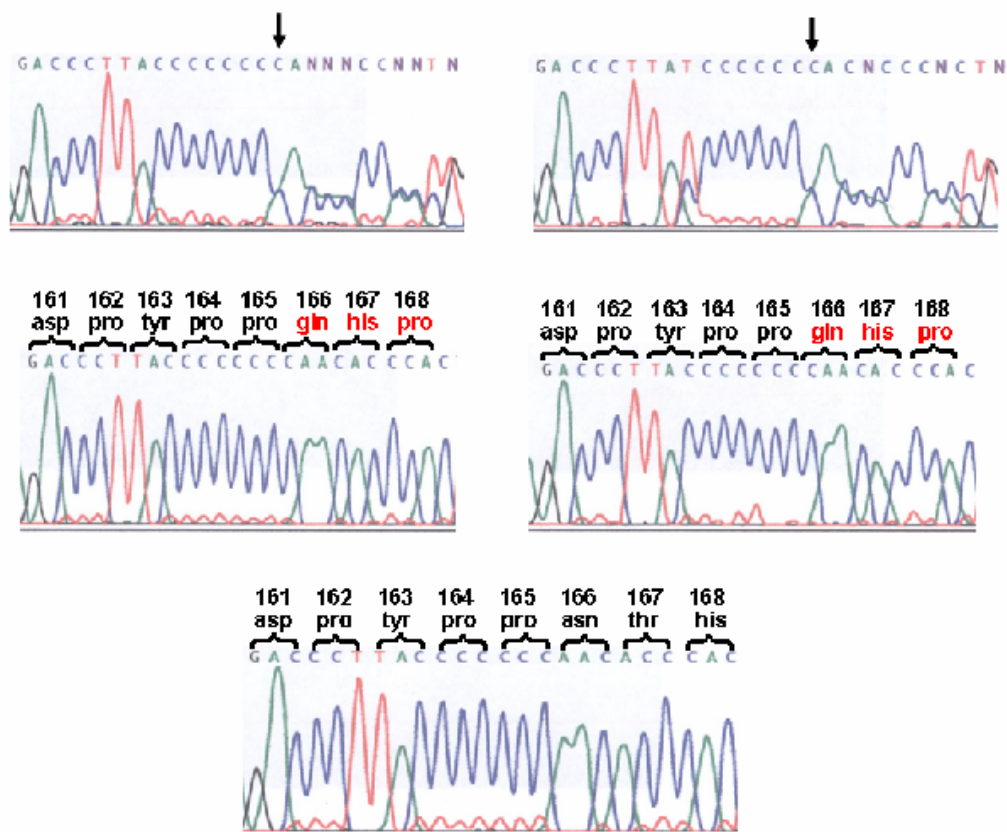


Figure 4.- Novel *MFRP* mutation. The *MFRPI* gene exon 5 partial nucleotide sequence analysis demonstrates a homozygous C insertion at nucleotide position 499 (codon 166) in affected individuals (middle panel, two affected DNA samples are shown). Amino acid numbers are indicated; frameshifted residues are in red. The mutation predicts a truncated MFRP protein (P165fsX198). Both parents were heterozygous for the mutation (top panel); arrows indicate the sequence frameshift. Control DNA sequence is shown for comparison (lower panel).

References

1. Wallman J, Winawer J. Homeostasis of eye growth and the question of myopia. *Neuron* 2004; 43:447-68.
2. Elder MJ. Aetiology of severe visual impairment and blindness in microphthalmos. *Br J Ophthalmol* 1994; 78:332-4.
3. Khairallah M, Messaoud R, Zaouali S, Ben Yahia S, Ladjimi A, Jenzri S. Posterior segment changes associated with posterior microphthalmos. *Ophthalmology* 2002; 109:569-74.
4. Traboulsi EI. Colobomatous microphthalmia, anophthalmia, and associated malformation syndromes. In: *Genetic Diseases of the Eye*. Traboulsi EI (ed) Oxford University Press, New York, 1998 .p. 51-80.
5. Weiss AH, Kousseff BG, Ross EA, Longbottom J. Simple microphthalmos. *Arch Ophthalmol* 1989; 107:1625-30.
6. Kallen B, Robert E, Harris J. The descriptive epidemiology of anophthalmia and microphthalmia. *Int J Epidemiol* 1996; 25:1009-16.
7. Fleckenstein M, Maumenee IH. Unilateral isolated microphthalmia inherited as an autosomal recessive trait. *Ophthalmic Genet* 2005; 26:163-168.

8. Spitznas M, Gerke E, Bateman JB. Hereditary posterior microphthalmos with papillomacular fold and high hyperopia. *Arch Ophthalmol* 1983; 101:413-7.
9. Goldblum D, Mojon DS. Posterior microphthalmos associated with papillomacular fold and high hyperopia. *J Pediatr Ophthalmol Strabismus* 1999; 36:351-2.
10. Kim JW, Boes DA, Kinyoun JL. Optical coherence tomography of bilateral posterior microphthalmos with papillomacular fold and novel features of retinoschisis and dialysis. *Am J Ophthalmol* 2004; 138:480-1.
11. Cross HE, Yoder F. Familial nanophthalmos. *Am J Ophthalmol* 1976; 31:300-6.
12. Ryan EA, Zwaan J, Chylack LT Jr. Nanophthalmos with uveal effusion: clinical and embryologic considerations. *Ophthalmology* 1982; 89:1013-7.
13. Vingolo EM, Steindl K, Forte R, Zompatori L, Iannaccone A, Sciarra A, Del Porto G, Pannarale MR. Autosomal dominant simple microphthalmos. *J Med Genet* 1994; 31:721-5.
14. Othman MI, Sullivan SA, Skuta GL, Cockrell DA, Stringham HM, Downs CA, Fornes A, Mick A, Boehnke M, Vollrath D, Richards JE. et al. Autosomal dominant nanophthalmos (NNO1) with high hyperopia and angle-closure glaucoma maps to chromosome 11. *Am J Hum Genet* 1998; 63:1411-8.

15. Yue BYJT, Kurosawa A, Duvall J, Goldberg MF, Tso MO, Sugar J. Nanophthalmic sclera. Fibronectin studies. *Ophthalmology* 1988; 95:56-60.
16. Buys YM, Pavlin CJ. Retinitis pigmentosa, nanophthalmos, and optic disc drusen: a case report. *Ophthalmology* 1999; 106:619-22.
17. Ghose S, Sachdev MS, Kumar H. Bilateral nanophthalmos, pigmentary retinal dystrophy, and angle closure glaucoma--a new syndrome? *Br J Ophthalmol* 1985; 69:624-8.
18. MacKay CJ, Shek MS, Carr RE, Yanuzzi LA, Gouras P. Retinal degeneration with nanophthalmos, cystic macular degeneration, and angle closure glaucoma. A new recessive syndrome. *Arch Ophthalmol* 1987; 105:366-71.
19. Mandal AK, Das T, Gothwal VK. Angle closure glaucoma in nanophthalmos and pigmentary retinal dystrophy: a rare syndrome. *Indian J Ophthalmol* 2001; 49:271-2.
20. Proenca H, Castanheira-Dinis A, Monteiro-Grillo M. Bilateral nanophthalmos and pigmentary retinal dystrophy. An unusual syndrome. *Graefes Arch Clin Exp Ophthalmol* 2006; 13:1-3.

21. Sundin OH, Leppert GS, Silva ED, Yang JM, Dharmaraj S, Maumenee IH, Santos LC, Parsa CF, Traboulsi EI, Broman KW, Dibernardo C, Sunness JS, Toy J, Weinberg EM. Extreme hyperopia is the result of null mutations in MFRP, which encodes a Frizzled-related protein. *Proc Natl Acad Sci USA* 2005; 102:9553-8.
22. Hermann P. Associated microphthalmia: microphthalmia-pigmentary retinitis-glaucoma syndrome. *Bull Soc Ophtalmol Fr* 1958; 46:42-5.
23. Franceschetti A, Gernet H. Diagnostic ultrasonique d'une microphthalmie sans microcornée, avec macrophakie, haute hypermetropie associée à une dégénérescence tapéto-rétiniennne, une disposition glaucomateuse et des anomalies dentaires. *Arch Ophthalmol (Paris)* 1965; 25:105-116.
24. Boynton JR, Pheasant TR, Levine MR. Hypoplastic optic nerves studied with B-scan ultrasonography and axial tomography of the optic canals. *Can J Ophthalmol* 1975; 10:473-81.
25. Lewis RA, Lee GB, Martonyi CL, Barnett JM, Falls HF. Familial foveal retinoschisis. *Arch Ophthalmol* 1977; 95:1190-6.
26. Lorentzen DW. Drusen of the optic disk. *Acta Ophthalmol* 1996; 1 (suppl 90):179-184.
27. Tso MOM. Pathology and pathogenesis of drusen of the optic nerve head. *Ophthalmology* 1981; 88:1066-80.

28. Grover S, Fishman GA, Brown J Jr. Frequency of optic disc or parapapillary nerve fiber layer drusen in retinitis pigmentosa. *Ophthalmology* 1997; 104:295-8.
29. Ferda Percin E, Ploder LA, Yu JJ, Arici K, Horsford DJ, Rutherford A, Bapat B, Cox DW, Duncan AM, Kalnins VI, Kocak-Altintas A, Sowden JC, Traboulsi E, Sarfarazi M, McInnes RR. Human microphthalmia associated with mutations in the retinal homeobox gene CHX10. *Nat Genet* 2000; 25:397-401.
30. Kameya S, Hawes NL, Chang B, Heckenlively JR, Naggert JK, Nishina PM. *Mfrp*, a gene encoding a frizzled related protein, is mutated in the mouse retinal degeneration 6. *Hum Mol Genet* 2002; 11:1879-86.
31. Sundin OH. The mouse's eye and *Mfrp*: not quite human. *Ophthalmic Genet* 2005; 26:153-155.
- 32.- Katoh M. Molecular cloning and characterization of MFRP, a novel gene encoding a membrane-type frizzled-related protein. *Biochem Biophys Res Commun* 2001; 282:116-23.
- 33.- van Raay T, Vetter ML. Wnt/Frizzled signaling during vertebrate retinal development. *Dev Neurosci* 2004; 26:352-58.
34. de Jongh RU, Abud HE, Hime GR. WNT/Frizzled signaling in eye development and disease. *Front Biosci* 2006;11:2442-64