

11201



UNIVERSIDAD NACIONAL  
AUTÓNOMA DE  
MÉXICO

FACULTAD DE MEDICINA

DIVISION DE ESTUDIOS DE POSGRADO E  
INVESTIGACION

SUBDIVISION DE ESPECIALIZACIONES  
MEDICAS

OFICIO FMED/SEM/1932/2004

**ASUNTO:** Autorización del trabajo de investigación  
del Dr. Braulio Martínez Benítez.

**DR. ISIDRO AVILA MARTINEZ**  
**SECRETARIO DE SERVICIOS ESCOLARES**  
**DE LA FACULTAD DE MEDICINA**  
**Presente.**

Estimado Dr. Avila Martínez:

Me permito informar a usted que el **Dr. Braulio Martínez Benítez**, alumno del curso de especialización en **Anatomía Patológica** en el **Instituto Nacional de Ciencias Médicas y de Nutrición "Salvador Zubirán"**, presenta el trabajo de investigación intitulado **"Pseudohyperplastic Prostatic Adenocarcinoma in Transurethral Resections of the Prostate"**.

De conformidad con el artículo 21 capítulo 5º. de las Normas Operativas del Plan Unico de Especializaciones Médicas (PUEM) se considera que cumple con los requisitos para validarlo como el trabajo formal de Investigación que le otorga el derecho de la diplomación como especialista.

Sin otro particular de momento, reciba un cordial saludo.

**Atentamente**

**"POR MI RAZA HABLARA EL ESPIRITU"**

**Cd. Universitaria, D. F. a 8 de septiembre de 2004**

**JEFE DE LA SUBDIVISION**

**DR. LEOBARDO C. RUIZ PEREZ**

LCRP\*ajr.

Braulio Martínez Benítez  
28 / sep / 04  
BM



Universidad Nacional  
Autónoma de México

Dirección General de Bibliotecas de la UNAM

**Biblioteca Central**




**UNAM – Dirección General de Bibliotecas**  
**Tesis Digitales**  
**Restricciones de uso**

**DERECHOS RESERVADOS ©**  
**PROHIBIDA SU REPRODUCCIÓN TOTAL O PARCIAL**

Todo el material contenido en esta tesis esta protegido por la Ley Federal del Derecho de Autor (LFDA) de los Estados Unidos Mexicanos (México).

El uso de imágenes, fragmentos de videos, y demás material que sea objeto de protección de los derechos de autor, será exclusivamente para fines educativos e informativos y deberá citar la fuente donde la obtuvo mencionando el autor o autores. Cualquier uso distinto como el lucro, reproducción, edición o modificación, será perseguido y sancionado por el respectivo titular de los Derechos de Autor.



INSTITUTO NACIONAL DE CIENCIAS MEDICAS Y NUTRICION  
SALVADOR ZUBIRAN

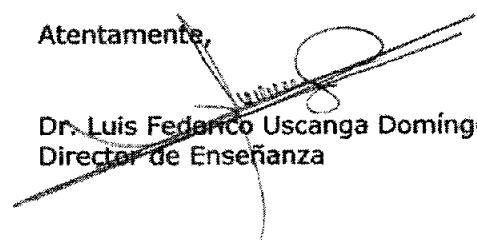
---

México, D.F., a 18 de agosto de 2004.

Dr. Enrique Graue Wiechers  
Jefe de la División de Estudios de Posgrado  
Facultad de Medicina, UNAM  
Presente

Por medio del presente, comunico a usted que por parte de esta Dirección de Enseñanza no tiene inconveniente alguno para que el **Dr. BRAULIO MARTINEZ BENITEZ**, médico residente de tercer año de la especialidad en Anatomía Patológica, realicé sus trámites necesarios para el diplomación oportuna con el artículo publicado en la Revista Pathology Oncology Research intitulado "**Pseudohyperplastic Prostatic Adenocarcinoma in Trasurethral Resections of the Prostate**"


Atentamente,

  
Dr. Luis Fedarico Uscanga Domínguez  
Director de Enseñanza



Investigación  
Tradición Servicio  
Asistencia Docencia  
20007700

- Vasco de Quiroga 15,
- Delegación Tlalpan
- C.P. 14000 México, D.F.
- Tels. 55-73-12-00
- 55-73-06-11



Entrez PubMed Nucleotide Protein Genome Structure PMC Journals Books

Search PubMed for

Limits Preview/Index History Clipboard Details

Abstract Show: 20 Sort Text

Entrez PubMed

1: Pathol Oncol Res. 2003;9(4):232-5. Epub 2003 Dec 22.

[Related Articles, Links](#)

[Pathol Oncol Res](#)  
Free Full Text

**Pseudohyperplastic prostatic adenocarcinoma in transurethral resections of the prostate.**

PubMed Services

**Arista-Nasr J, Martinez-Benitez B, Valdes S, Hernandez M, Bornstein-Quevedo L.**

Department of Pathology, Instituto Nacional de Ciencias Medicas y de la Nutricion Salvador Zubiran, Tlalpan, 14000, Mexico. pipa5@hotmail.com

Related Resources

Pseudohyperplastic prostatic adenocarcinoma is a recently described variety of adenocarcinoma that has been studied in core-needle biopsies and prostatectomy specimens. It is characterized by malignant glands that simulate benign hyperplastic glands with complex, medium to large-sized glands with papillary infoldings, luminal undulations, branching or cystic dilatations, and columnar cells with macronucleoli and nuclear enlargement. Our aim was to define frequency, tumor volume, and histologic features of pseudohyperplastic prostatic adenocarcinoma in transurethral resections of prostate. We studied 250 specimens from transurethral resections; 150 specimens were originally diagnosed as benign glandular hyperplasia, and 100 as conventional prostate adenocarcinomas. Of the 150 biopsies originally diagnosed as benign glandular hyperplasia, two (1.3%) had areas of pseudohyperplastic carcinoma. In both cases the neoplasm was limited to two chips and measured 3 and 4 mm in diameter, respectively. Both patients were asymptomatic 2 and 4 years after diagnosis. Of the 100 biopsies with adenocarcinoma, areas of pseudohyperplastic carcinoma were found in three cases. In the first two these areas were found in two fragments, and in the other case they were found in three chips, and measured 3, 4, and 6 mm, respectively. The clinical course in these cases was unfavorable, and two patients had metastasis. Main histologic findings included crowded glands (5/5), papillary projections (5/5), nuclear enlargement (5/5) macronucleoli (4/5) cystic glandular dilatation (4/5) straight luminal borders (4/5), pink amorphous secretions (4/5) nuclear hyperchromasia (3/5) and transition to small acinar pattern of adenocarcinoma (3/5). In conclusion, pseudohyperplastic prostate carcinoma is rare in transurethral resection specimens and is found in scarce chips. Frequency of false negative results in biopsies originally diagnosed as benign glandular hyperplasia was 1.3%. In biopsies diagnosed as carcinoma, this frequency was 3%. These patients had an adverse clinical course, apparently due to association with areas of conventional adenocarcinoma.

PMID: 14688829 [PubMed - in process]

Abstract Show: 20 Sort Text

## ARTICLE

## Pseudohyperplastic Prostatic Adenocarcinoma in Transurethral Resections of the Prostate

Julián ARISTA-NASR, Braulio MARTINEZ-BENITEZ, Samuel VALDES, Mercedes HERNÁNDEZ,  
Leticia BORNSTEIN-QUEVEDO

Department of Pathology, Instituto Nacional de Ciencias Médicas y de la Nutrición Salvador Zubirán, Tlalpan, México

Pseudohyperplastic prostatic adenocarcinoma is a recently described variety of adenocarcinoma that has been studied in core-needle biopsies and prostatectomy specimens. It is characterized by malignant glands that simulate benign hyperplastic glands with complex, medium to large-sized glands with papillary infoldings, luminal undulations, branching or cystic dilatations, and columnar cells with macronucleoli and nuclear enlargement. Our aim was to define frequency, tumor volume, and histologic features of pseudohyperplastic prostatic adenocarcinoma in transurethral resections of prostate. We studied 250 specimens from transurethral resections; 150 specimens were originally diagnosed as benign glandular hyperplasia, and 100 as conventional prostate adenocarcinomas. Of the 150 biopsies originally diagnosed as benign glandular hyperplasia, two (1.3%) had areas of pseudohyperplastic carcinoma. In both cases the neoplasm was limited to two chips and measured 3 and 4 mm in diameter, respectively. Both patients were asymptomatic 2 and 4 years after diagnosis. Of the 100 biopsies

with adenocarcinoma, areas of pseudohyperplastic carcinoma were found in three cases. In the first two these areas were found in two fragments, and in the other case they were found in three chips, and measured 3, 4, and 6 mm, respectively. The clinical course in these cases was unfavorable, and two patients had metastasis. Main histologic findings included crowded glands (5/5), papillary projections (5/5), nuclear enlargement (5/5) macronucleoli (4/5) cystic glandular dilatation (4/5) straight luminal borders (4/5), pink amorphous secretions (4/5) nuclear hyperchromasia (3/5) and transition to small acinar pattern of adenocarcinoma (3/5). In conclusion, pseudohyperplastic prostate carcinoma is rare in transurethral resection specimens and is found in scarce chips. Frequency of false negative results in biopsies originally diagnosed as benign glandular hyperplasia was 1.3%. In biopsies diagnosed as carcinoma, this frequency was 3%. These patients had an adverse clinical course, apparently due to association with areas of conventional adenocarcinoma. (Pathology Oncology Research Vol 9, No 4, 232-235)

**Keywords:** pseudohyperplastic prostatic adenocarcinoma, diagnosis

### Introduction

Pseudohyperplastic prostatic adenocarcinoma (PHPA) is characterized by malignant glands that simulate benign hyperplastic glands. This neoplasm shows complex, medium to large-sized glands with papillary infoldings, luminal undulations, branching, or cystic dilations. Morphologic features used to identify PHPA include columnar

cells with basal nuclei, which show nucleomegaly and nucleolar enlargement and absence of basal cells.

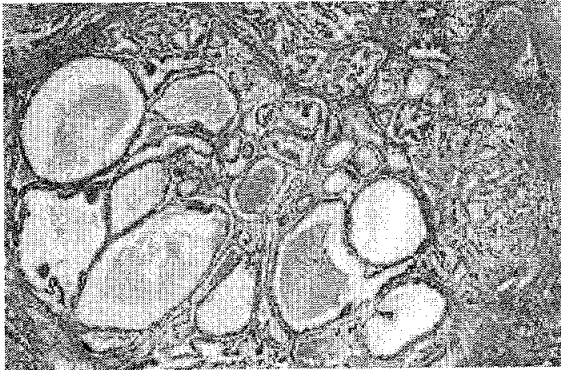Although some features of this neoplasm were mentioned in the literature many years ago,<sup>1,3</sup> only recently have the main morphologic features and frequency of these neoplasm in needle biopsies and radical prostatectomies been studied.<sup>4,6</sup> The aim of this report was to investigate frequency, extension and morphologic features of PHPA in transurethral resections of prostate (TURP).

### Materials and Methods

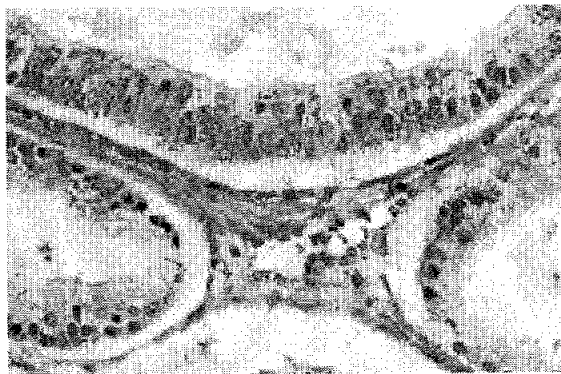
We studied 250 consecutive transurethral prostate resections, 150 diagnosed as benign nodular hyperplasia and 100 diagnosed as prostate adenocarcinoma. Cases of glandular

Received: June 25, 2003; accepted: Oct 10, 2003

Correspondence: Julian ARISTA-NASR, MD, Instituto Nacional de Ciencias Médicas y de la Nutrición Salvador Zubirán, Vasco de Quiroga No. 15, Tlalpan, 14000, México, D.F., Mexico, Phone: (+52-5)573-1200, exts. 2184 and 2186, E-mail: pipa5@hotmail.com



**Figure 1.** Pseudohyperplastic carcinoma. Neoplastic glands form a well-circumscribed nodule and exhibit variability in diameter, cystic dilatation, and papillary foldings. Some show amorphous secretions and corpora amylacea. Areas of transition to small acinar pattern of adenocarcinoma are observed (right). (hematoxylin-eosin x 50)



**Figure 2.** Detail of Figure 1. Pseudohyperplastic carcinoma. Neoplasm shows columnar cells with cleared cytoplasm, nuclear enlargement, and prominent nucleoli (hematoxylin-eosin x 575)

dular hyperplasia were included, considering that some biopsies with hyperplasia could have been mistaken for PHPA. In addition, age, prostate specific antigen (PSA) level, and clinical course of patients with PHPA were obtained from medical records.

To calculate tumor volume of pseudohyperplastic carcinoma, total number of fragments obtained in transurethral resection, number of tissue fragments with PHPA, and their diameter in millimeters were counted. In each case, the following histologic criteria were assessed: number of chips with PHPA, growth pattern, crowded glands, papillary projections, cystic glandular dilatations, straight luminal borders, macronucleoli, double nucleoli, nuclear enlargement, nuclear hyperchromasia, clear cytoplasm, columnar epithelium, intraluminal amorphous pink mater-

ial, intraluminal blue mucin, corpora amylacea, intraluminal crystalloids, mitotic figures, perineural invasion, collagenous micronodules, glomerulations, adjacent prostatic intraepithelial neoplasia (PIN), and transition to small acinar pattern of adenocarcinoma, Gleason grade and Gleason score. Immunohistochemical studies using high-molecular weight-keratin (34 beta E12, 1:150; Dako Corp., Carpinteria, Ca, USA) were performed as described previously.<sup>7</sup>

### Results

The number of fragments analyzed in each biopsy varied from 95 to 132 chips (average, 115 chips). Two of the 150 (1.3%) consecutive TRUP biopsies originally diagnosed as glandular hyperplasia showed PHPA. In both cases, PHPA was observed only in two chips and neoplastic foci measured 3 and 4 mm, respectively. Patients were aged 62 and 70 years. Their clinical course 2 and 4 years after diagnosis was good and there were no clinical symptoms of carcinoma; PSA was 3.5 ng/ml and 5 ng/ml, respectively.

Three (3%) of the 100 biopsies with carcinoma demonstrated areas with PHPA, two fragments in two cases, and three fragments in another case. The size was 3, 4, and 6 mm respectively. Patients were aged between 69 and 73 years; their clinical course was unfavorable. Two patients exhibited metastasis 3 and 4 years after diagnosis, and the third patient had carcinoma with obstructive symptoms despite radiotherapy.

Percentage of chips with PHPA in all five cases was less than 2% of tissue fragments examined. Pseudohyperplastic foci formed well-circumscribed nodules (Figures 1,2), (Gleason pattern 1 and 2, Gleason sum 3, 4), which resembled benign glandular hyperplasia at low magnification; only one case exhibited areas of complex branching pattern with small intraluminal projections and undulations (Figure 3). In no case was an infiltrative pattern observed. Neoplastic glands showed closely packed glands (5/5) with papillary projections (5/5), cystic glandular dilatation (4/5), straight luminal borders (4/5), pink amorphous secretions (4/5) and corpora amylacea (2/5) (Figure 1). Neoplastic cells resembled hyperplastic cells in the columnar-like aspect and clear cytoplasm; however, unlike hyperplastic glands, cells with PHPA exhibited focal or diffuse nucleomegaly (5/5), hyperchromasia (3/5) and occasional-to-frequent nucleoli (4/5) (Figures 2,4); in two of these cases, we also observed double nucleolus in some of the neoplastic cells (Figure 2). One case from the group of hyperplasias had atypical mitosis.

The most useful findings to recognize neoplastic areas at low magnification were the close arrangement of neoplastic glands and continuity with areas of small acinar pattern of adenocarcinoma (Figure 1). This change was observed in two cases of the hyperplasia group and in one of the

biopsies of conventional adenocarcinoma. Immunohistochemical stains showed absence of basal cells in all PHPA areas (Figure 5).

In the group of 100 biopsies with conventional adenocarcinoma, the most frequent Gleason patterns were 3, 4, and 5, and Gleason score varied between 6 and 9. Two PHPA were associated with poorly differentiated carcinoma (Gleason patterns 8 and 9), and another one with moderately differentiated carcinoma (Gleason score 6).

### Discussion

Pseudohyperplastic prostatic carcinoma is an uncommon variety of adenocarcinoma. Humphrey et al. found it in 2% of 100 adenocarcinomas in sextant 18-gauge prostate needle biopsy and 22 of 202 (11%) cases of adenocarcinoma in prostatectomies.<sup>4</sup> The pseudohyperplastic area comprised 2% of needle biopsy tissue and 5% of total carcinoma length. We found a similar frequency (2.2%) of PHPA in a study of 135 sextant needle biopsies.<sup>6</sup>

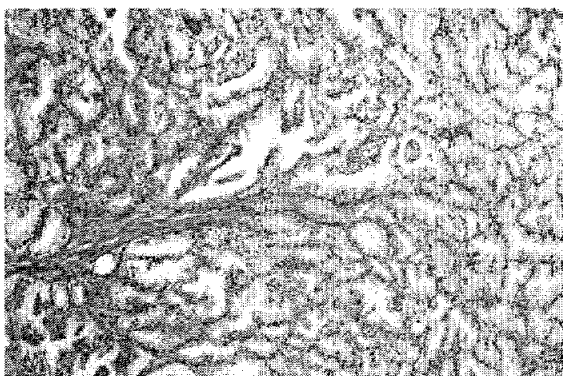


Figure 3. Complex branching pattern of pseudohyperplastic carcinoma. Intraluminal papillary projections and luminal undulations are shown. (hematoxylin-eosin x 85)

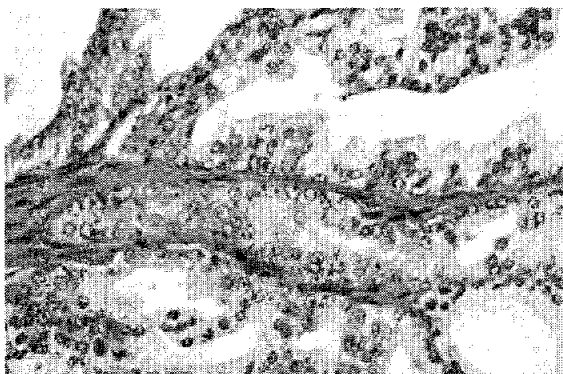


Figure 4. High magnification of Figure 3. The majority of the cells show nuclear enlargement and macronucleoli. (hematoxylin-eosin x 720)

In the 22 cases of PHPA in prostatectomies studied by Humphrey,<sup>4</sup> 12 were located at the periphery of prostate, and 10 were found in the transition zone. Mean diameters of pseudohyperplastic foci was 1 mm in needle biopsy and 3 mm (range 1-7 mm) in radical prostatectomy; in addition, they were in direct continuity with either well-differentiated Gleason pattern 2 or moderately differentiated carcinoma Gleason pattern 3. Levi and Epstein<sup>5</sup> studied 20 cases received in consultation in which PHPA was the predominant pattern of the neoplasm (at least 60%, and in most cases, 90%). Of the 20 cases studied by these authors, 16 were needle biopsies, two transurethral resections, and two, enucleations. This authors found that the first key to recognize the malignant nature of pseudohyperplastic prostate cancer at low magnification consisted of presence of crowded glands; other findings included presence of papillary infoldings in neoplastic glands, large atypical glands, branching, nuclear enlargement, pink amorphous secretions, occasional-to-frequent nucleoli, and crystalloids. Features associated with malignancy (mitosis, blue-tinged mucin, adjacent high-grade PIN, and perineural invasion) were infrequent.

Our study was performed to define frequency, tumor volume, and histologic characteristics of pseudohyperplastic carcinoma in transurethral resections. Humphrey et al.<sup>4</sup> mentioned that the incidence of PHPA in TURP is unknown. In the two cases studied by Levi and Epstein,<sup>5</sup> carcinoma in both TURP represented 5% or less (3 and 5 mm) of reviewed material. In addition, Epstein described and illustrated the appearance of this neoplasm in his textbooks.<sup>8-9</sup>

In our series, areas with PHPA were found in two of 150 biopsies initially diagnosed as glandular hyperplasia, and in three of 100 biopsies with adenocarcinoma. Areas with PHPA were observed in 2 or 3 chips and represented approximately between 1 and 2% of all fragments examined. Size of foci with PHPA varied between 3 and 6 mm.

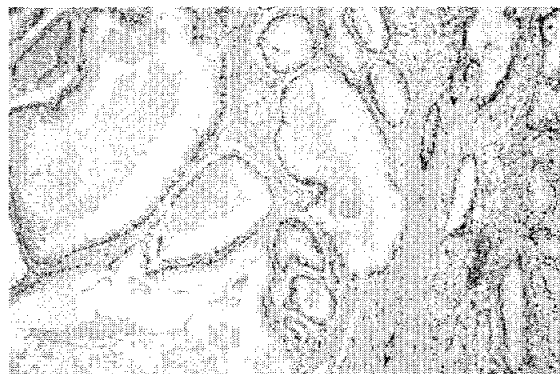

Figure 5. Immunostaining for high-molecular-weight keratin shows absence of basal cells in neoplastic glands (left) and a positive stain in adjacent benign glands (right). (x 50).

**Table 1. Frequency of histologic features in pseudohyperplastic carcinoma on five transurethral prostatic resections**

Histologic features	No. cases
Crowded glands	5/5
Papillary projections	5/5
Nuclear enlargement	5/5
Clear epithelium	5/5
Columnar epithelium	5/5
Macronucleoli	4/5
Cystic glandular dilatation	4/5
Straight luminal borders	4/5
Pink amorphous secretions	4/5
Nuclear hyperchromasia	3/5
Transition to small acinar pattern of adenocarcinoma	3/5
Corpora amylacea	2/5
Double nucleoli	2/5
Mitosis	1/5
Blue mucin	0/5
Intraluminal crystalloids	0/5
Perineural invasion	0/5
Collagenous micronodules	0/5
Glomerulations	0/5
Adjacent PIN	0/5

#### PIN-Prostatic intraepithelial neoplasia

These findings suggest that PHPA in transurethral resections is not only infrequent, but that it is also found in isolated fields. Because of its similarity with benign glandular hyperplasia, PHPA can often be overlooked when transurethral resections are analyzed, inasmuch as it is only found in small, isolated fields. However, it must be emphasized that percentage of false negative results appears to be infrequent. In this study, only 1.3% of biopsies originally diagnosed as hyperplasia were found to have areas of PHPA. The small percentage of PHPA in transurethral resections could be explained by the findings of Humphrey et al.<sup>4</sup> In the analysis of 202 prostatectomies, in which pseudohyperplastic change, when present, was only 6% of total tumor size.

In the group of 100 conventional adenocarcinomas, three cases exhibited chips with PHPA, and only one was continuous with small acinar pattern of adenocarcinoma. Areas of conventional prostate adenocarcinoma did not show transition with PHPA chips, even when chips with Gleason patterns of 3, 4, or 5 were observed in numerous fields. Although additional studies are needed to know the clinical course of pseudohyperplastic carcinoma when found in small fragments obtained in TURP, the two cases of PHPA originally diagnosed as benign glandular hyperplasia had a favorable clinical course 2 and 4 years after diagnosis and there was no evidence of neoplastic activity.

When PHPA is associated with moderately or poorly differentiated prostate adenocarcinoma, PHPA represents a lower percentage of the neoplasm and the prognosis will depend on the areas of conventional adenocarcinoma.

When most of the neoplasm consists of pseudohyperplastic carcinoma, as in the cases studied by Levin and Epstein,<sup>5</sup> prognosis is uncertain; however, it must be noted that these authors encountered cases with extraprostatic extension and invasion into seminal vesicles. These findings suggest that PHPA should not be equated with low-grade prostatic carcinoma.<sup>5</sup> Although pseudohyperplastic carcinoma is difficult to grade because the Gleason scoring system does not account for this histologic pattern,<sup>5</sup> we found in all cases well-circumscribed nodules which resembled Gleason pattern 1 and 2, (Gleason score 3 and 4).

Differential diagnosis of PHPA must be established mainly with nests of hyperplastic glands. Occasionally prostatic intraepithelial neoplasia can exhibit crowded glands of variable diameter with papillary tufts and atypia that resemble PHPA.<sup>10</sup> Unlike PHPA, PIN usually does not exhibit cystic glandular dilatation, amorphous secretions, or corpora amylacea, and it maintains basal cells in varying proportions. When in doubt, the use of high-molecular-weight keratin can establish the distinction.<sup>5,7</sup> Prostatic adenosis may exhibit scattered, large glands admixed with small crowded glands, which makes it easy to discriminate from pseudohyperplastic carcinoma.<sup>11</sup>

#### References

- Muir EG. Carcinoma of the prostate. *Lancet* 1:667-72,1934
- Willis RA. Pathology of tumors. ST. Louis: CV Mosby; 1948, p587.
- Ackerman LV. Surgical Pathology. St. Louis: CV Mosby; 1964:651.
- Humphrey PA, Kaleem Z, Swanson PE, Vollmer RT. Pseudohyperplastic prostatic adenocarcinoma. *Am J Surg Pathol* 22: 1239-46, 1998
- Levi A, Epstein JI. Pseudohyperplastic prostatic adenocarcinoma on needle biopsy and simple prostatectomy. *Am J Surg Pathol* 24:1039-46,2000
- Arista-Nasr, Cortes E, Picardo R. Low grade adenocarcinoma simulating benign glandular lesions in needle prostatic biopsy. *Rev Invest Clin* 49:37-40,1997
- Wojno KJ, Epstein JI. The utility of basal cell specific anticytokeratin antibody (34 beta E12) in the diagnosis of prostate cancer: a review of 228 cases. *Am J Surg Pathol* 19:251-60,1995
- Epstein JI. Variants of prostatic adenocarcinoma. In: Prostate Biopsy Interpretation. New York, NY: Lippincott-Raven, 1989, pp169-73.
- Epstein JI. Evaluation of transurethral resection specimens. In: Prostate Biopsy Interpretation. Philadelphia: Lippincott-Raven, 1995, pp143-4.
- Bostwick DG, Amin MB, Dundore P et al. Architectural patterns of high grade prostatic intraepithelial neoplasia. *Hum Pathol* 24:298-310,1993
- Bostwick DG, Srigely J, Grignon D et al. Atypical adenomatous hyperplasia of the prostate: morphological criteria for its distinction from well differentiated carcinoma. *Hum Pathol* 24:819-32,1993